

# *Clinical and Radiological Findings of the Middle Ear' Embryonal Rhabdomyosarcoma and Temporal Bone in the Children*

## *Achados Clínicos e Radiológicos do Rabdomiossarcoma Embrionário de Orelha Média e Osso Temporal em Crianças*

***José Roberto Lopes Ferraz-Filho\**, *Leonardo Franco Felipe\*\**, *Valdeci Hélio Floriano\*\**,  
*Eduardo Moreira de Queiroga\*\*\**, *Bruno Doriguetto Couto Ferreira\*\*\*\**, *Antônio Soares Souza\*\*\*\*\**.**

\* PhD. Radiologist.

\*\* Master. Radiologist.

\*\*\* Specialization in Pathology. Pathologist.

\*\*\*\* Specialization in Radiology. Radiologist.

\*\*\*\*\* PhD. Head of the Department of Radiology.

Institution: Medicine School of São José do Rio Preto - Hospital of Base  
São José do Rio Preto/ SP- Brazil.

Mail Address: José Roberto Ferraz Filho - Av Brigadeiro Faria Lima, 5544 - São José do Rio Preto/ SP - Brazil - ZIP CODE: 15090-000 - Phone: (+55 11) 3201-5743  
- E-mail: jrl.ferraz@terra.com.br

Article received on December 15, 2008. Approved on July 4, 2009.

### **SUMMARY**

**Introduction:**

The rhabdomyosarcoma is a sarcoma of soft parts more common in the children. It is considered a malignant neoplasm derivative of the striated skeletal muscle and, which is originated in any part of the body. The head, neck, orbit, cranial base, nasal cavity and nasopharynx are the local of origin most common.

**Case Report:**

We describe a uncommon presentation of the embryonal rhabdomyosarcoma in a four-year-old child, with synchronous lesions in the cranial base, middle ear and, frontal bone emphasizing the clinical and radiological findings.

**Keywords:**

rhabdomyosarcoma, middle ear, temporal bone, child, magnetic resonance imaging.

### **RESUMO**

**Introdução:**

O rabdomiossarcoma é o sarcoma de partes moles mais comum em crianças. É considerado uma neoplasia maligna derivada do músculo esquelético estriado e que se origina em qualquer parte do corpo. A cabeça, pescoço, órbita, base do crânio, cavidade nasal e nasofaringe são os sítios de origem mais comuns.

**Relato do Caso:**

Descrevemos uma apresentação incomum do rabdomiossarcoma embrionário em uma criança de 4 anos, com lesões sincrônicas na base do crânio, orelha média e osso frontal, enfatizando os achados clínicos e radiológicos.

**Palavras-chave:**

rabdomiossarcoma, orelha média, osso temporal, criança, ressonância magnética.

## INTRODUCTION

The rhabdomyosarcoma is an aggressive tumour accounting for 5-8% of all pediatric malignancies and for over 50% of all soft tissue sarcomas in children (1-5). It is considered a malignant neoplasia derived from striated muscle arising in any part of the body, however, it is more common in regions of the head and neck, genitourinary tract, retroperitoneum and extremities (3-5). Approximately 30% of all pediatric rhabdomyosarcomas occur in the head and neck and common sites of origin are the orbits, base of the skull, nasal cavity and nasopharynx. In nasopharynx, usually, it involves the middle ear, paranasal sinus and masticatory space (5).

Rhabdomyosarcomas are classified based on histopathologic features, which have distinct clinical characteristics: embryonal (the most common type in infants and young children), alveolar, botryoid, spindle cell and anaplastic variants (6).

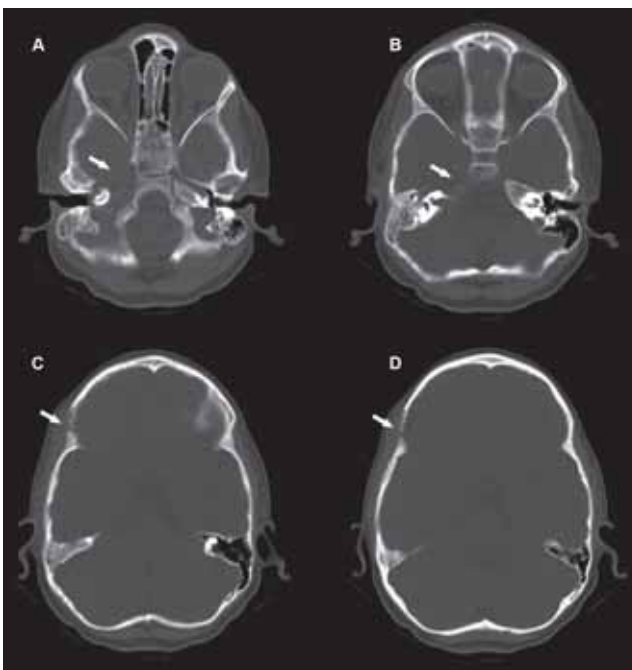
The purpose of this study is to report a case of middle ear and temporal bone embryonal rhabdomyosarcoma associated with exudative otitis media emphasizing both clinical and radiological findings.

## CASE REPORT

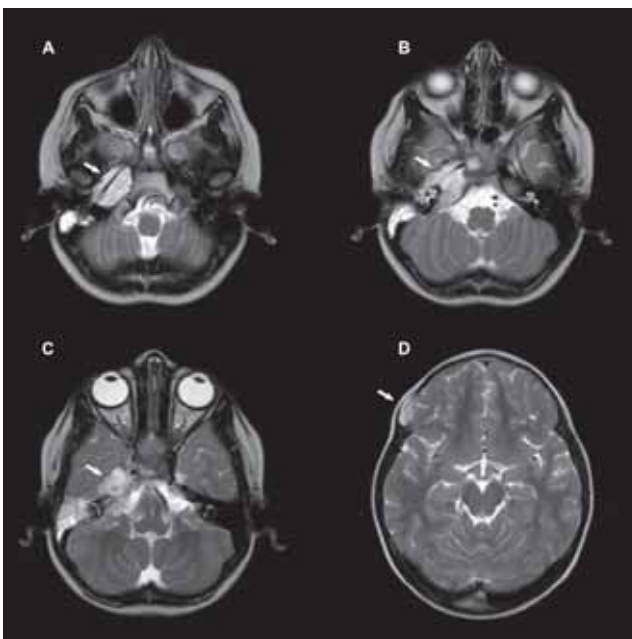
A boy, aged 4 years, presenting otalgia and irritability for the last 30 days where was diagnosed an otitis media. After a short course of antibiotics and analgesics the child developed deviation of the eye to the right, facial paralysis, and hearing impairment on the right.

The neurologic examination findings included facial and abducens nerve palsy on the right. The otoscopic examination showed a fragile and reddish tissue in the external acoustic meatus. The tympanic membrane was intact presenting hyperemia and bulging. Pure-tone audiometry detected a 45-dB hearing loss in this ear. There was no detectable lymphadenopathy on palpation.

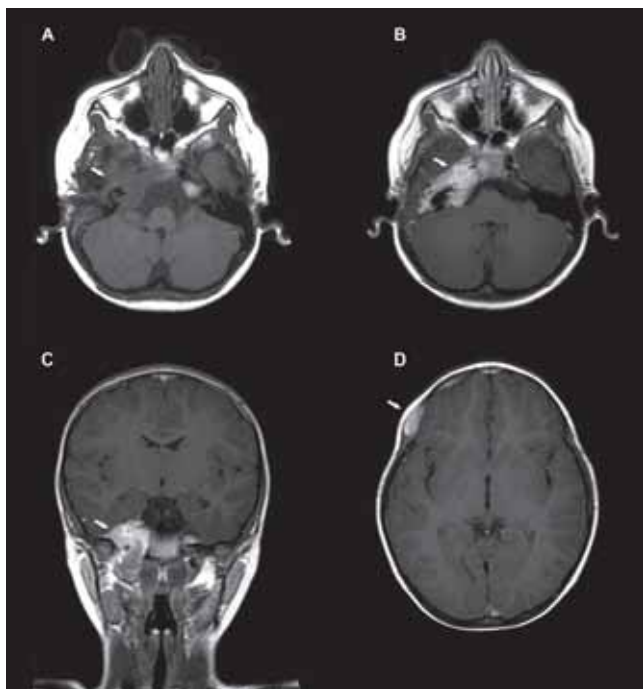
A computed tomography (CT) of the head showed destruction of the petrous part of temporal bone and right carotid canal associated another lesion with soft-tissue component in the right frontal bone (Picture 1). The magnetic resonance imaging (MRI) showed lesions hypointense in T1-weighted sequences and hyperintense in T2-weighted sequences (Picture 2) with contrast enhancement (Picture 3) located in the petrous part of right temporal bone, middle ear and clivus. In association, it was observed a lesion in the right frontal bone along with the coronal suture.



**Picture 1.** CT showed destruction of the petrous part of temporal bone, carotid canal on the right (A,B) and right frontal bone (C,D).



**Picture 2.** MRI T2 weighted images showed synchronic hyperintense lesions with soft-tissue component located in the petrous part of right temporal bone extending to the sphenoid and clivus (A,B,C) and associated with lesion of right frontal bone (D).



**Picture 3.** MRI T1 weighted images showed hypointense lesion located in the petrous part of right temporal bone (A), with contrast enhancement (B,C) and associated with lesion of right frontal bone (D).

The impairment of the right abducens nerve has occurred by involvement of Dorello canal and the facial and vestibulocochlear nerve by involvement of the internal acoustic meatus and the ipsilateral tympanic cavity.

Biopsy of the right external acoustic meatus showed chronic otitis externa with granulation tissue and rare atypical cells. The immunohistochemical methods confirmed, through the antibody expressions for desmin and myogenin, the diagnosis of embryonal rhabdomyosarcoma.

The tumor was resected by radical mastoidectomy via postauricular with meatoplasty and the child was started on multiagent chemotherapy and radiotherapy.

This study was approved by the Ethics Research Committee of the Institution.

## DISCUSSION

Embryonal is the most common histologic subtype of rhabdomyosarcomas. It is responsible for 70 to 80% of the presentations and its origin is supposed to be triggered by a disorder in mesenchymal primitive differentiation of the musculoskeletal cells in their first or earliest stages of embryogenesis (3,7,8).

Rhabdomyosarcomas may have their origin in any anatomical localization occurring predominantly in head and neck regions, orbits, skull base, nasal cavity, and nasopharynx where there is little or no musculoskeletal tissue (1,9). In pediatric cases, about 30 to 40% occur in the head and neck regions (10), however, the ear and the temporal bone are uncommon sites of involvement (7,8,11).

Middle ear rhabdomyosarcomas were reported in the literature with a range of symptoms that clinically simulates chronic otitis media. The most common are facial nerve palsy, headache, hearing impairment, and bleeding (5). However, the findings of facial palsy with involvement of nerve roots and lesions of the perineural and parameningeal spaces are more suggestive of malignancy. Enlarged lymphonodes are more likely associated with distant metastasis (5,7).

Metastasis can be present in up to 30% of the cases. The most common affected sites are the lungs, liver, bones and extremities (5,12). In our case, the early diagnosis was otitis media followed of the paralysis of the cranial nerves by involvement of the space perineural and presence of distant frontal bone lesion.

The MRI study is the exam of choice because it more precisely defines the extent of tumor, as well as its signal pattern, boundaries, and post-contrast enhancement (13,14). In the case reported the lesion presented predominantly hyperintense in T2-weighted sequences, hypointense in T1-weighted sequences with homogeneous contrast enhancement and impairment of the perineural space.

Rhabdomyosarcomas affecting the perineural and parameningeal spaces, nasopharynx, paranasal sinuses, and temporal bone, generally are not amenable to surgical resection. In these areas, there is increased risk of serious damage to cranial nerves and deformation of the facial skeleton by radical surgery, and it is unlikely to complete resection. The treatment of choice for these tumors is chemotherapy and radiotherapy, with surgery limited to diagnostic biopsy (7,11).

Plexiform neurofibromas, juvenile angiofibroma, non-Hodgkin lymphoma, nasopharyngeal carcinoma, histiocytosis and cholesteatoma must be included among the differential diagnosis (15).

The diagnosis of middle ear and the temporal bone rhabdomyosarcoma is difficult when associated inflammatory-infectious diseases, such as exudative otitis media that may mask the base disease and delay the definite diagnosis. In these cases, early correlation with imaging screenings is essential.

---

## BIBLIOGRAPHICAL REFERENCES

---

1. Arita K, Sugiyama K, Tominaga A, Yamasaki F. Intracellular rhabdomyosarcoma: case report. *Neurosurgery*. 2001, 48(3):677-680.
2. Kim EE, Valenzuela RF, Kumar AJ, Raney RB, Eftekari F. Imaging and clinical spectrum of rhabdomyosarcoma in children. *Clin Imaging* 2000, 24(5):257-262.
3. Ho RH, Johnson J, Dev VG, Whitlock JA. A novel t(2;20)(q35;p12) in embryonal rhabdomyosarcoma. *Cancer Genet Cytogenet*. 2004, 151(1):73-77.
4. Cil T, Altintas A, Isikdogan A. Rhabdomyosarcoma presenting with destructive large lesion of the face. *South Med J*. 2008, 101:104-105.
5. Durve DV, Kanegaonkar RG, Albert D, Levitt G. Pediatric rhabdomyosarcoma of the ear and temporal bone. *Clin Otolaryngol Allied Sci*. 2004, 29(1):32-37.
6. Parham DM, Ellison DA. Rhabdomyosarcomas in adults and children: an update. *Arch Pathol Lab Med*. 2006, 130(10):1454-1465.
7. Sbeity S, Abella A, Arcand P, Quintal MC, Saliba I. Temporal bone rhabdomyosarcoma in children. *Int J Pediatr Otorhinolaryngol*. 2007, 71(5):807-814.
8. Andrassy RJ. Rhabdomyosarcoma. *Semin Pediatr Surg*. 1997, 6:17-23.
9. Viswanatha B. Embryonal rhabdomyosarcoma of the temporal bone. *Ear Nose Throat J*. 2007, 86(4):218-222.
10. Goto TK, Yoshiura K, Tanaka T, Kanda S, Ozeki S, Ohishi M, et al. A follow-up of rhabdomyosarcoma of the infratemporal fossa region in adults based on the magnetic resonance imaging findings: case reports. *Oral Surg Oral Med Oral Pathol Oral Radiol Endod*. 1998, 86(5):616-625.
11. Daya H, Chan HS, Sirkin W, Forte V. Pediatric rhabdomyosarcoma of the head and neck: is there a place for surgical management? *Arch Otolaryngol Head Neck Surg*. 2000, 126(4):468-472.
12. Binokay F, Soyupak SK, Inal M, Celiktas M, Akgul E, Aksungur E. Primary and metastatic rhabdomyosarcoma in the breast: report of two pediatric cases. *Eur J Radiol*. 2003, 48(3):282-284.
13. Yang WT, Kwan WH, Li CK, Metreweli C. Imaging of pediatric head and neck rhabdomyosarcomas with emphasis on magnetic resonance imaging and a review of the literature. *Pediatr Hematol Oncol*. 1997, 14(3):243-257.
14. Lee JH, Lee MS, Lee BH, Choe DH, Do YS, Kim KH, et al. Rhabdomyosarcoma of the head and neck in adults: MR and CT findings. *Am J Neuroradiol*. 1996, 17:1923-1928.
15. Dickson PV, Davidoff AM. Malignant neoplasms of the head and neck. *Semin Pediatr Surg*. 2006, 15:92-98.